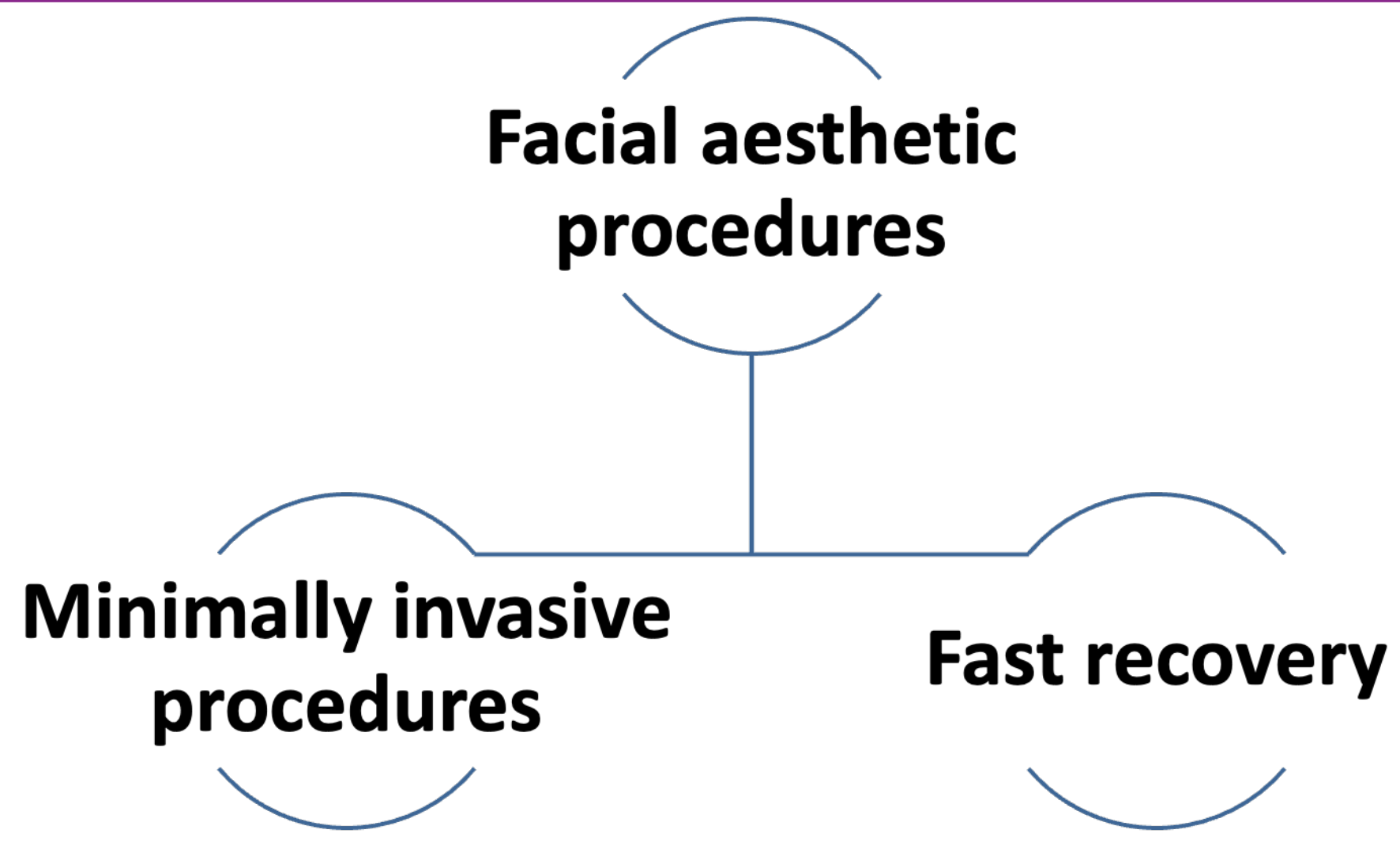


INTRODUCTION



INTRODUCTION

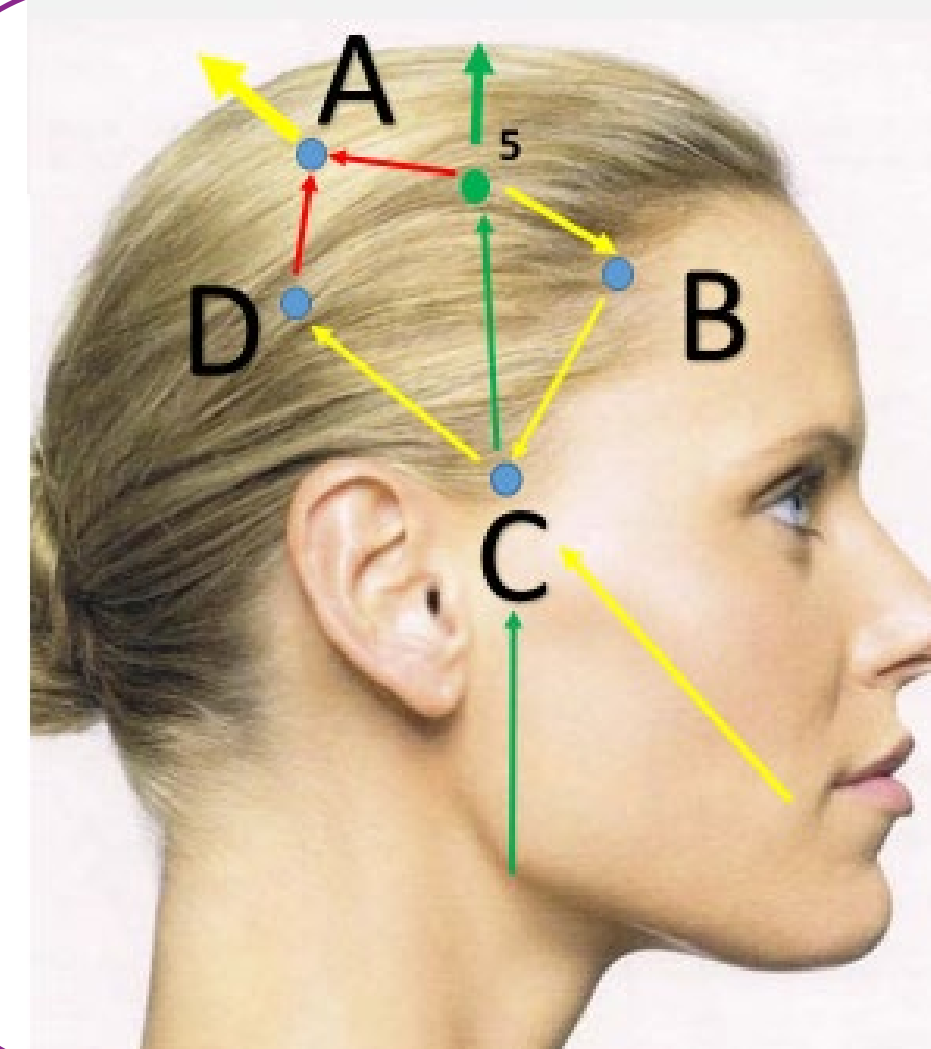
Naturalness Musculoaponeurotic suspension Anchorage in temporal muscle region

Significant facial changes
Fresh-faced

CASE REPORT

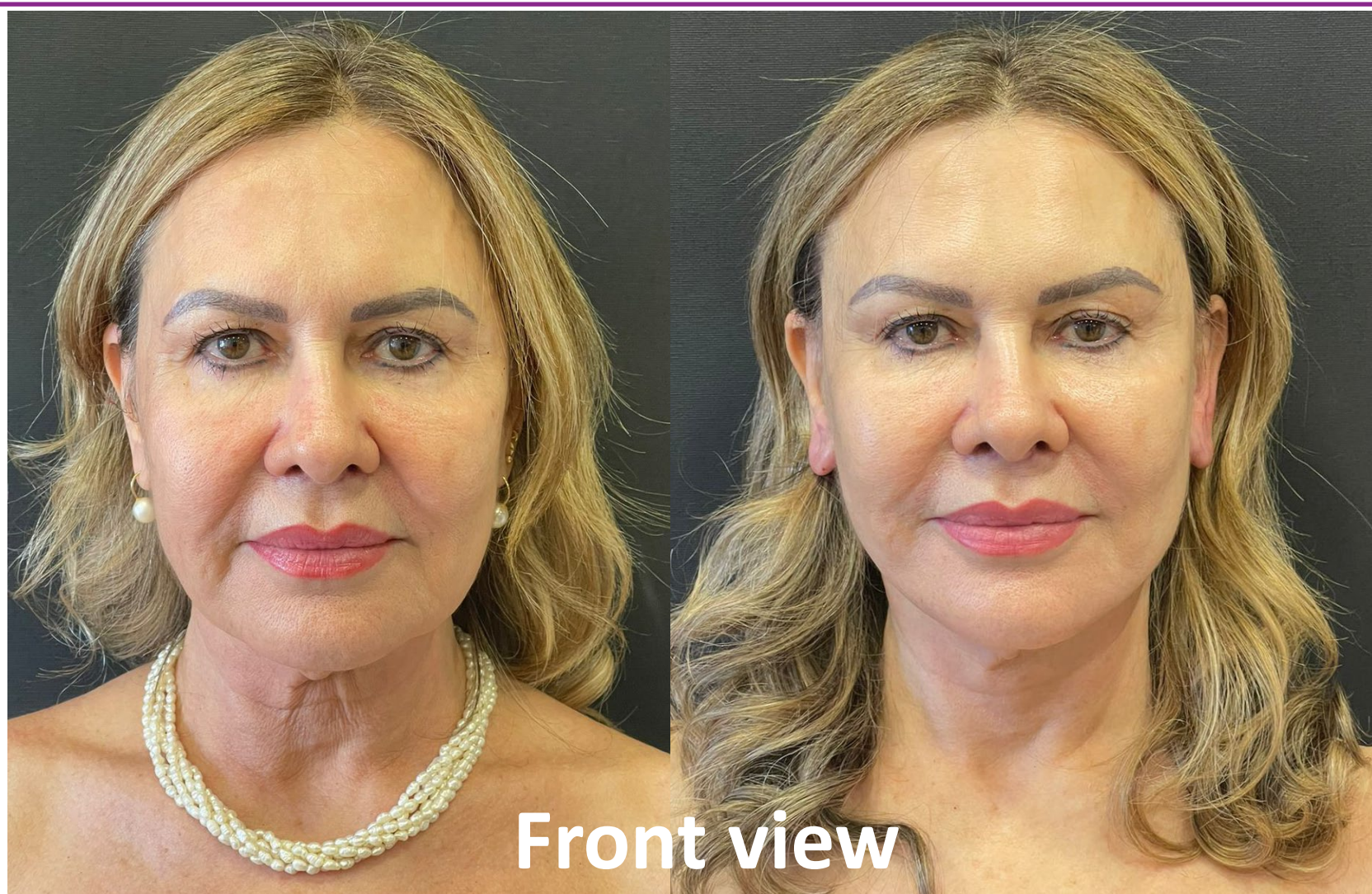Patient L.T, 62 years old, female, presented as her main complaint the melting of the face with loss of mandibular contour, accentuated Chinese mustache, drooping eyebrows and upper and lower eyelids and breakage of the puppet line. The patient did not want to undergo facial fillers with hyaluronic acid in order not to lose her facial naturalness, so she underwent a non-surgical facelift.

CASE REPORT



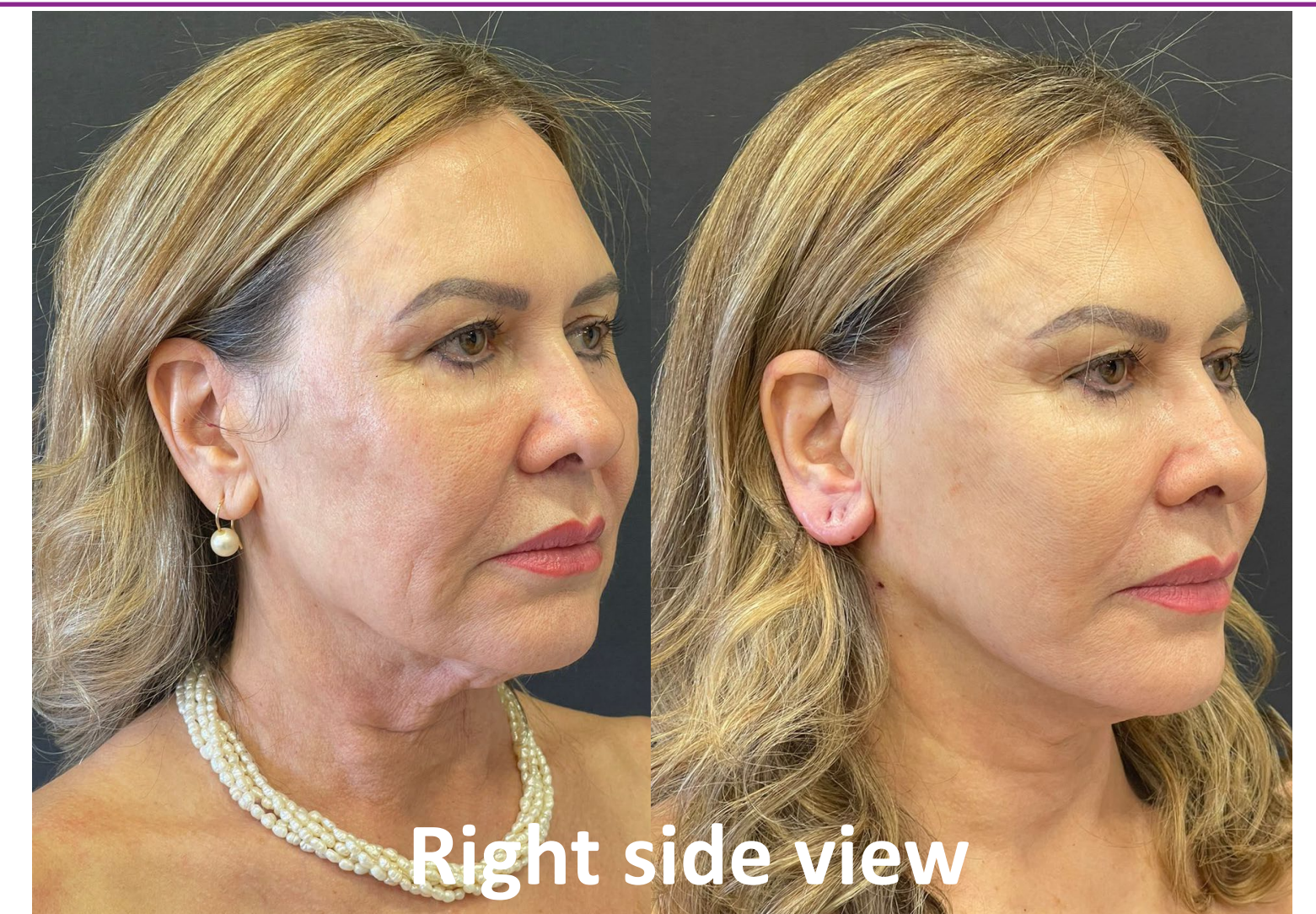Face Lift appointments

RESULTS

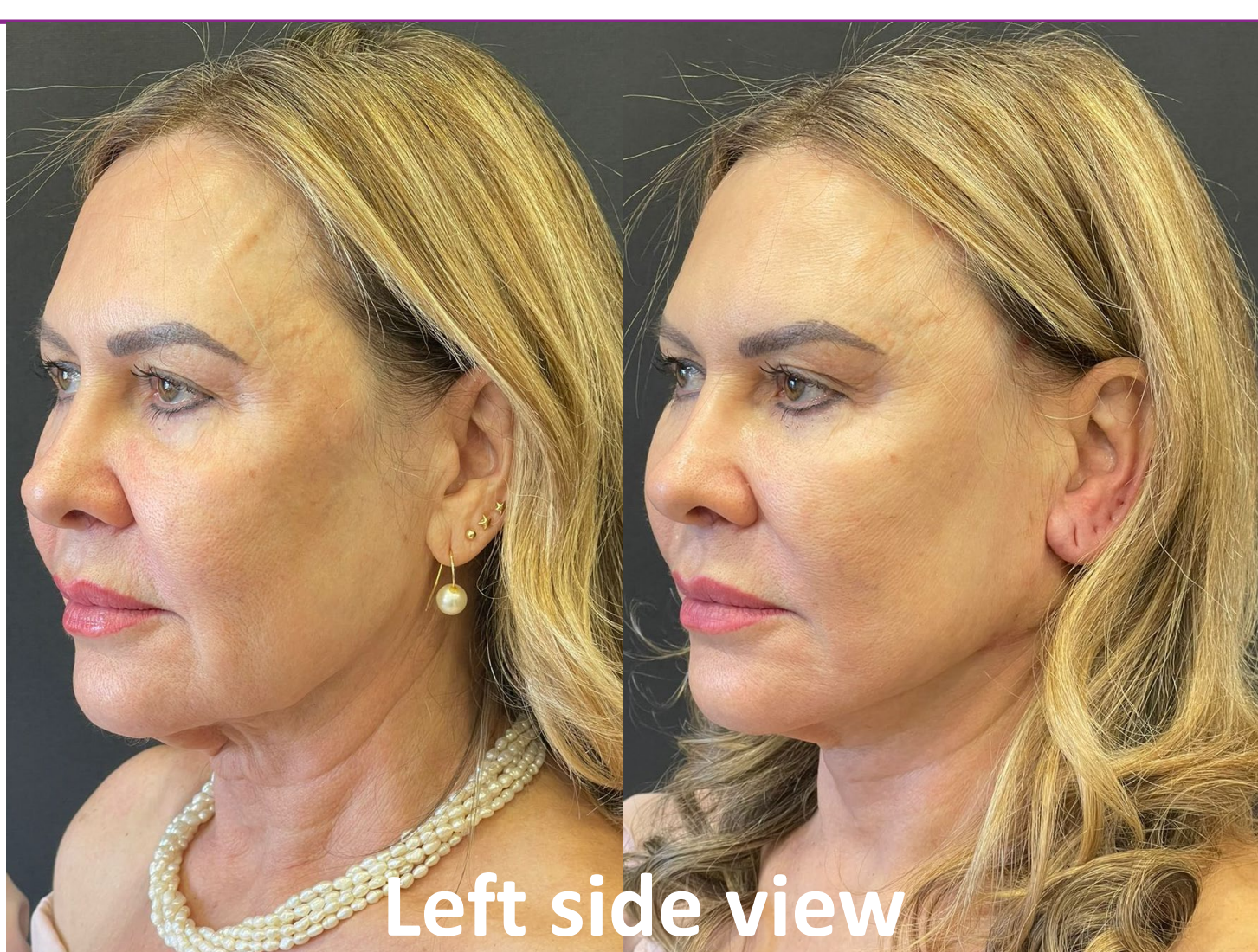

Front view

RESULTS



Right side view



Left side view

RESULTS

After 6 months, the maintenance of the satisfactory result was verified. It is important to highlight the maintenance of the result by associating botulinum toxin, fillers, biostimulators, subdermal diode laser. There was a significant improvement in the signs of aging in the middle third and even in the cervical region.

RESULTS

There was local discomfort with intense pain that progressed to mild in the first three days after the procedure, which was controlled with the use of analgesics. Despite the discomfort, the patient did not need to leave her usual activities. Tissue elevation was no longer observed 40 days after the procedure. No complications have been reported in this case to date.

CONCLUSION

Tissue repositioning, as described in this paper, manages to temporarily resolve the main complaint of melting in the middle third of the face, producing satisfactory results.

